

3D Printed Tubular Guides for Pedicle Screw Placement: The Answer for the Need of a Greater Accuracy in Spinal Stabilization

Alessandro Landi^{*}, Fabrizio Gregori, Cristina Mancarella and Roberto Delfini

Department of Neurology and Psychiatry, Division of Neurosurgery, University of Rome Sapienza, Rome, Italy

^{*}**Corresponding author:** Alessandro Landi, MD, PhD, Department of Neurology and Psychiatry, Division of Neurosurgery, University of Rome Sapienza, Viale del Policlinico 155, 00161 Rome, Italy. Tel: +39 0649979105; E-mail: dott.alessandro.land@gmail.com

Received date: July 20, 2015, **Accepted date:** July 21, 2015, **Published date:** July 30, 2015

Copyright: ©2015 Landi A, et al. This is an open-access article distributed under the terms of the Creative Commons Attribution License, which permits unrestricted use, distribution, and reproduction in any medium, provided the original author and source are credited.

Keywords: 3D printed tubular guides; Spinal stabilization; Screw placement; Spinal neuronavigazione; Spine; Surgery

pedicle entry point, screw position and screw dimensions (diameter and length).

Introduction

Vertebral stabilization with pedicle screws is currently considered the gold standard for many conditions, such as degenerative, traumatic and oncologic pathologies of the spine [1].

The need for a more accurate surgical technique has led, during the years, to the research of methods and technical aids in order to reach the most accurate and safe pedicle screw placement, for clinical and medico-legal reasons.

The estimated screw misplacement rate varies in the literature in a range from 6 to 31% with the free-hand technique and from 15 to 72% with the fluoroscopic guided technique, the two most widespread techniques [2-7].

Recently, many different systems have been developed in order to help the spinal surgeon in the placement of pedicle screws, and to reduce the incidence of misplacement. The most used system is surely the neuronavigator [8]. Widely known and applied in oncologic brain surgery, its use is increasingly widespread also in spine surgery. A preoperative surgical planning is performed on the basis of a thin slice CT scan, with a margin of error starting from 0.5 mm.

Despite its high cost, today a neuronavigator is available in the majority of neurosurgical departments.

Another device, currently in the preliminary phase of use, is the robotic arm [9]: it has to be fixed on the patient or to the surgical table and, basing on the preoperative planning, provides the planned orientation for the pedicle probe both for open and for percutaneous procedures. The use of this instrument is still limited, because of its recent commercialization and its high cost.

3-D printed guides

Alternative devices of recent introduction are the 3D-printed tubular guides, realized in a customized manner with 3D printers on a preoperative thin slice CT scan. Their aim is to orient and guide in a precise fashion the placement of the screw in the pedicle.

The first step is the radiological study. A thin slice CT scan involving the vertebrae that need to be instrumented is performed. After that, the study is uploaded on an digital platform, where specifically trained engineers elaborate a graphic study in a three-dimensional environment, including a 3D model of the patient's spine anatomy and preoperative planning with precise identification of the

The surgeon, constantly connected with the digital platform of the producing firm, can modify each parameter of the planning, varying the trajectory of insertion, incrementing or reducing the diameter and/or the length of the screws, according to personal preferences, until he decides a final planning.

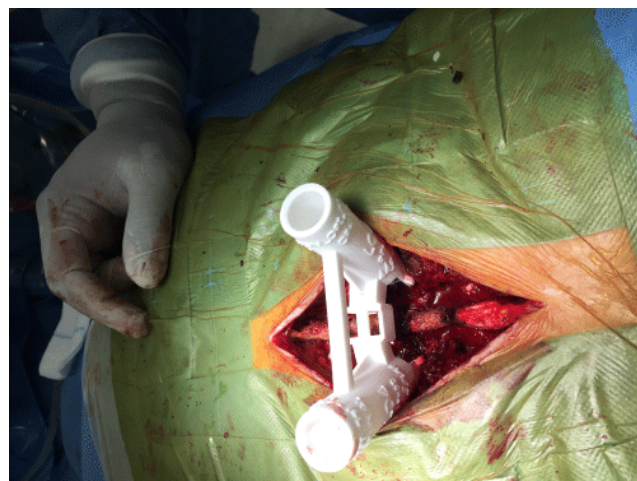

Figure 1: The 3-D printed tubular guide applied into the surgical wound.

With the data contained in the final version of the planning, the tubular guides and a 3D model of the involved vertebrae are printed with a 3D printer (Figure 1). The 3D vertebral model is used by the surgeon to identify the anatomic landmarks where the tubular guides are in contact with the patient's vertebra, carefully exposed and isolated during surgery.

The tubular guides have contact points on the spinous process, the pars interarticularis and the transverse process. Therefore the surgical exposure of those anatomical landmarks has to be extremely accurate to allow a correct contact between the tubular guides and the vertebrae (Figure 2).

Once the involved vertebrae and the aforementioned landmarks have been exposed, the surgeon places the tubular guides on the vertebra and, with different instruments and adapters, places the screws in the planned position (Figure 3). During the procedure the surgeon can, at any moment, change the dimensions of the screws

(diameter and length) or convert the intervention to the classical technique.

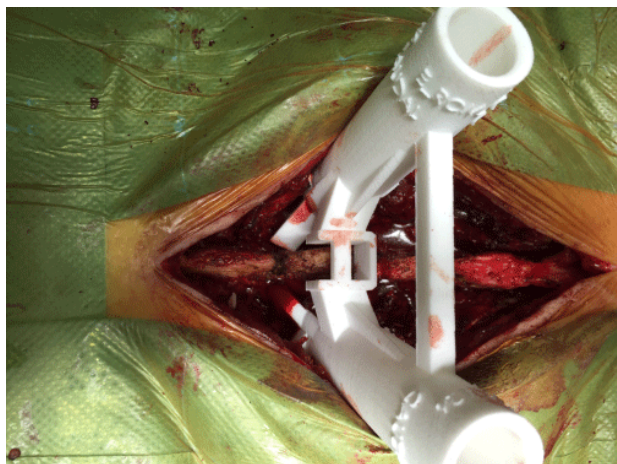

Figure 2: The 3D-printed tubular guide applied into the surgical wound.

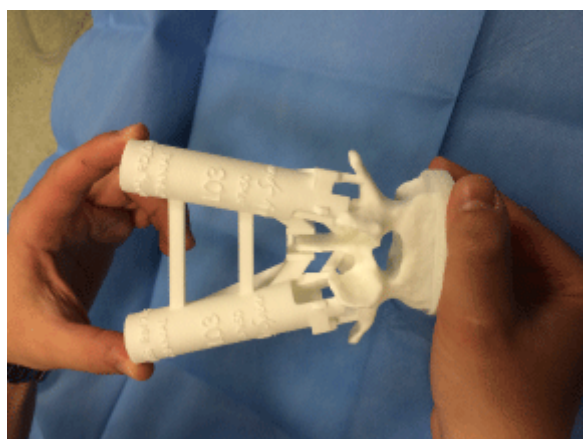


Figure 3: The 3-D printed tubular guide and the 3-D model of L3 vertebra.

The system does not require the use of intraoperative fluoroscopy to place the screws, but it is advisable, in the first uses of those guides, to perform an initial fluoroscopic check, in order to assess the correct placement of instruments and screws.

Advantages and disadvantages

The main advantage offered by this device, is the level of accuracy in pedicle screw placement, with a maximum margin of error of 0.5 mm, corresponding to the minimum margin of error of the common neuronavigation techniques. So, the screw placement can be considered “safe”. Furthermore, this level of accuracy is absolutely useful for patients with spinal deformities, whose common anatomical landmarks can be in an abnormal position or might be not easily recognizable. The system is particularly useful in these very cases, because the preoperative study, made on the computer, allows an

optimal planning in a surgical field otherwise difficult. Another important aspect is the possibility to study preoperatively the diameter and the length of the screws. In this way the surgeon can exploit all the space available in the vertebral body, increasing the grip of the screws and the rigidity of the system. A further advantage is the reduction of the intraoperative use of fluoroscopy, with benefits both for the patient and the surgical staff.

Disadvantages of this technique are: the wide exposition of the anatomical structures for the placement of the tubular guides (also necessary for the placement of the landmark for neuronavigation, so it is comparable to the latter) and the time needed between the approval of the plan and the printing of the guides (about 20 days). So this solution is not suitable in cases of emergency surgery and in cases of percutaneous screw placement, but only with the open technique.

Conclusions

The 3D tubular guides system for pedicle screw placement is a new method that seems to considerably reduce the rate of screw misplacement. There are risks indeed, mainly related to the preoperative planning made by the surgeon. In relation to this, it has to be underlined that this system’s aim is not to make spine surgery easy for everyone and to simplify the technique for the non-experts. The system rather requires the surgeon to have a good experience in screw placement with the “classic” technique. This competence allows indeed both to perform an adequate and optimal planning, and to overtake some “debacles” of the system.

Although there are minimal disadvantages, if a future implementation of new features will lead to guides requiring a less extensive exposure of the anatomical structures, this system could be a good alternative to neuronavigation techniques for the assisted placement of pedicle screws in the thoraco-lumbar spine, with a considerably inferior margin of error.

References:

1. Joglekar SB, Mehdod (2012) Surgeon's view of pedicle screw implantation for the monitoring neurophysiologist. *J Clin Neurophysiol* 29: 482-488.
2. Gelalis ID, Paschos NK, Pakos EE, Politis AN, Arnaoutoglou CM, et al. (2012) Accuracy of pedicle screw placement: a systematic review of prospective in vivo studies comparing free hand, fluoroscopy guidance and navigation techniques. *Eur Spine J* 21: 247-255.
3. Tian NF, Huang QS, Zhou P, Zhou Y, Wu RK, et al. (2011) Pedicle screw insertion accuracy with different assisted methods: A systematic review and meta-analysis of comparative studies. *Eur Spine J* 20: 846-859.
4. Tian NF, Xu HZ (2009) Image-guided pedicle screw insertion accuracy: A meta-analysis. *Int Orthop* 33: 895-903.
5. Kosmopoulos V, Schizas C (2007) Pedicle screw placement accuracy: a meta-analysis. *Spine (Phila Pa 1976)* 32: 111-120.
6. Puvanesarajah V, Liauw JA, Lo S-F, Lina IA, Witham TF (2014) Techniques and accuracy of thoracolumbar pedicle screw placement. *World J Orthop* 5: 112-123.
7. Nevzati E, Marbacher S, Perrig W, et al. (2012) Accuracy of Pedicle Screw Placement in the Thoracic and Lumbosacral Spine Using Conventional Intraoperative Fluoroscopy Placement Technique: A Single-Center Analysis of 1236 Consecutive Screws. *J Neurol Surg Part A Cent Eur Neurosurg* 73: 866-871.
8. Helm P, Teichman R, Hartmann S, Simon D (2015) Spinal Navigation and Imaging: History, Trends and Future. *IEEE Trans Med Imaging* 0062: 1-1.
9. Stürer C, Ringel F, Stoffel M, Reinke A, Behr M, et al. (2011) Robotic technology in spine surgery: current applications and future developments. *Acta Neurochir Suppl* 109: 241-245.